

# A retrospective analysis of mature cystic teratomas of the ovary: a cross sectional study from a tertiary care hospital of central region of Nepal



Maharjan S<sup>1</sup>, Tiwari M<sup>2</sup>, Ranabhat S<sup>3</sup>

## Correspondence to:

[sushnamaharjan74@gmail.com](mailto:sushnamaharjan74@gmail.com)

<sup>1</sup>**Dr. Sushna Maharjan**, MBBS, MD, Assistant Professor, Department of Pathology, Chitwan Medical College, Bharatpur-10, Chitwan, Nepal.

<sup>2</sup>**Dr. Mamata Tiwari**, MBBS, MD, Associate Professor.

<sup>3</sup>**Dr. Sabin Ranabhat**, MBBS, MD, Associate Professor.

### All authors are affiliated to

Department of Pathology, Chitwan Medical College, Bharatpur-10, Chitwan, Nepal.

### Editors for this Article:

Dr. A.K. Pradhan, MBBS, MD. Professor, KIMS, Amalapuram, Editor-In-Chief, Medical Science.

Dr. Arnab Ghosh, MBBS, MD, Professor, Pathology, MCOMS, Editorial board member, Medical Science.

Dr. Indrajit Banerjee, MBBS, MD, Asst. Professor, Pharmacology, DYP Mauritius, DYP Mauritius, Editorial board member, Medical Science.

### Cite this article:

Maharjan S, Tiwari M, Ranabhat S. A retrospective analysis of mature cystic teratomas of the ovary: a cross sectional study from a tertiary care hospital of central region of Nepal. *Medical Science*. 2014, 2(4):150-6.

### Information about the article

**Received:** August 28, 2014

**Revised:** Oct. 29, 2014

**Accepted:** Nov. 12, 2014

**Published online:** Dec. 30, 2014

## Abstract

### Background

Mature cystic teratoma (MCT), usually known as dermoid cysts derived from primordial germ cells. Comparing with different other types of germ cell tumors like dysgerminomas, and endodermal sinus tumors, they are most commonly observed. The aim of this study was to evaluate the prevalence, clinical and pathological characteristics; and complications of MCT of the ovary in Chitwan district, central region of Nepal.

### Methods

A retrospective, hospital based study was carried out in all histopathologically proven cases of MCT from July 2011 to June 2014. Relevant data were retrieved from the records of Pathology Department of Chitwan Medical College-Teaching Hospital. According to the guidelines of World Health Organization (WHO), classification of ovarian tumors was done mainly based on histogenetic principles.

### Results

Seventy four MCTs were studied from 62 patients. Majority of the patients (74.19%) were in reproductive age group of 21-40years. Chief complaint was abdominal pain. Ascites was the most common complication found in 6.45% patients. The rate of torsion was 4.84%; larger tumors underwent torsion more frequently than smaller tumors ( $P < 0.05$ ). Right-sided tumors outnumbered the left-sided tumors. The bilaterality rate was 19.35%.

### Conclusion

Integrated MCT accounts for 49% of all ovarian neoplasm and occur principally during the reproductive years. Postmenopausal women or children sometimes affected. Prevalence rates of torsion were relatively less. Larger tumors have more risk of undergoing torsion than smaller tumors.

### Key words

Ascites, germ layer derivative, mature cystic teratomas, Nepal, torsion.



## Background

Mature cystic teratoma of the ovary is commonly known as the dermoid cyst which contains developmentally mature skin-related structures with hair follicles and sweat glands. It is originated from primordial germ cells and histologically composed of three well-differentiated elements, namely ectoderm, mesoderm and endoderm [1-3]. Although Germ cell layer derivatives originated mainly from the ectoderm, but there are frequent evidences of mesodermal and endodermal derivatives [4]. It accounts for approximately 15% of all ovarian neoplasms [1, 2]. It is not only the most common germ cell tumor [5], also the most common ovarian tumor in patients between 20 to 40 years of age [6]. Majority of the cases, patients admitted in the hospital with a clinical presentation of acute pelvic pain and mass [4]. Relatively fewer occurrences (10-15%) of MCT documented bilaterally [1, 2, 7]. Torsion, rupture and infection are the most common complains among MCT patients [8, 9]. The possibility of the development of a malignancy should be considered in case of tumors with a diameter larger than 10 cm, in women aged over 45 years [10]. Growth rate of MCTs are slow, at an average rate of 1.8 mm each year, which may prompt clinician towards nonsurgical management of relatively smaller (<6-cm) tumors [11]. Although there are several studies of MCT in Asian countries, from Nepal reports are less [12, 13]. Bashyal and Lee reported three cases of MCT from Chitwan, but there was no retrospective cross sectional analysis to understand the epidemiological scenario of the disease [14, 15]. The prognosis for malignant transformation of MCT is very poor with a five year survival of only 15-30%. So early diagnosis is required [13]. This is the first study to investigate the prevalence, clinical and pathological characteristics; and complications in MCT cases in the Bharatpur district, central region of Nepal.

## Material and Methods

### Study Period

Three years records of MCT (July 2011 to June 2014) was collected for this study from the Department of Pathology in Chitwan Medical College Teaching Hospital, Bharatpur-10 Chitwan, Nepal.

### Study design and the collection of data

It was a retrospective, hospital based study conducted in the Department of Pathology. A total number of 151 ovarian neoplasms were analyzed in this study, among them, 74 cases of MCTs in 62 patients (bilaterality in 12 patients). All the histopathologically confirmed cases of MCTs were considered for this study. We included all the cases, specimens were received and processed in the Department of Pathology of this hospital. Sociodemographic details,

patient's history, complications, clinical features, diagnosis, types of surgical interventions, were retrieved from the departmental records. Conventional techniques were followed in processing the tissues. Tissues were fixed in 10% buffered solution of formalin, a series of treatments performed and as a routine procedure embedded in paraffin. Sections were cut into 5 micron or even thinner when necessary and stained with routine Hematoxylin and Eosin (H & E) stain using standard procedure. The WHO classification of ovarian tumors was used for categorizing the tumors [16].

### Inclusion criteria

All the histopathologically confirmed cases of ovarian MCTs included, for this study irrespective of age or any other factors.

### Exclusion criteria

Incomplete sociodemographic records or clinical history of the patients were excluded to avoid study bias.

### Ethical committee approval

The samples used in this study were from routine clinical specimens. This is a retrospective study and not interfering with routine clinical care so written permission was obtained at the beginning of the experiment from the Head of the Department, Pathology, Chitwan Medical College Teaching Hospital.

### Outcome variable

Clinical manifestations like abdominal pain, discomfort, pelvic pain, tumor related complications, tumor diameter were set up as outcome variable.

### Explanatory variables

The demographic factors were considered as explanatory variables

### Data management and statistical analysis

Data were expressed as mean, median, range, number and percentages. Comparison was made and the two-tailed student t-test and Mann Whitney U-test was used as appropriate. Probability level of  $P < 0.05$  was considered statistically significant.

## Results

Out of a total number of 151 cases of ovarian neoplasms, 74(49%) cases of MCTs of the ovary in 62 patients (including bilaterally in 12 patients) were diagnosed.



Age(years)	Number of patients - n(%)
1-10	1(1.61)
11-20	5(8.06)
21-30	34(56.45)
31-40	12(19.35)
41-50	7(11.29)
51-60	0(0)
61-70	2(3.22)
71-80	1(1.61)

Table - 1 shows the age distribution of patients. The age range of the patients was 10-76 years with a median of 27.5 years and mean ( $\pm$ SD) of  $30.87 \pm 12.43$  years, six patients (9.67%) were postmenopausal and 2(3.22%) were perimenopausal. Majority of the patients, 46 (74.19%) were in reproductive age group of 21-40 years. Two pediatric patients were of ages 10 and 14 years old.

Manifestations	Number of patients n(%)
<b>Asymptomatic</b>	14(22.58)
<b>Symptomatic</b>	
Chronic abdominal pain	35(56.45)
Abdominal pain 40(64.52%) Acute abdominal pain (with torsion and rupture peritonitis)	4(6.45)
Abdominal pain with menorrhagia	1(1.61)
<b>Abdominal discomfort or distension</b>	8(12.90)
<b>Pelvic pain</b>	1(1.61)

Table - 2 explains abdominal pain was the most frequent symptom of presentation in 40(64.52%) of patients. Four patients who presented with acute abdominal pain had complications of torsion and rupture peritonitis. There were no relevant complaints in 14 patients (22.58%) in whom diagnosis was made during pelvic surgery for other reason or during a routine pelvic examination. The tumor was diagnosed in two pregnant women during cesarean section.

Table - 3 explains complications of tumor and right-sided tumors outnumbered the left-sided tumors: 34 (54.83%) to 16 (25.80%). There was no statistically significant difference between the size of right- and left-sided tumors. Bilateral tumors were detected in 12 (19.35%) patients. The size of 74 MCTs (including 12 bilateral cases) ranged from 3 to 25 cm in its maximum diameter with a median of 7.25 cm and mean of  $8.21 \pm 3.94$  cm. Most of the tumors, 85.14% (63/74) were in between 5 to 15 cm in diameter and 5.40% (4/74) were larger than 15 cm.

On cut section, almost all tumors 73/74 (98.64%) were cystic; most of them were unilocular, filled with yellow cheesy material and tufts of hair.

Complications n(%)	
Ascites	4 (44.44%)
Torsion	3 (33.33%)
Infection	1 (11.11%)
Rupture peritonitis	1 (11.11%)
<b>Total</b>	9(100)
Tumor diameter (cm)	
	P value
Tumors undergoing torsion	19 $\pm$ 3.60 0.029*
Tumors without torsion	7.76 $\pm$ 3.26
Right-sided tumors	8.72 $\pm$ 4.6 0.459*
Left-sided tumors	7.37 $\pm$ 2.35

P<0.05, statistically significant  
 \*P>0.05, statistically not significant

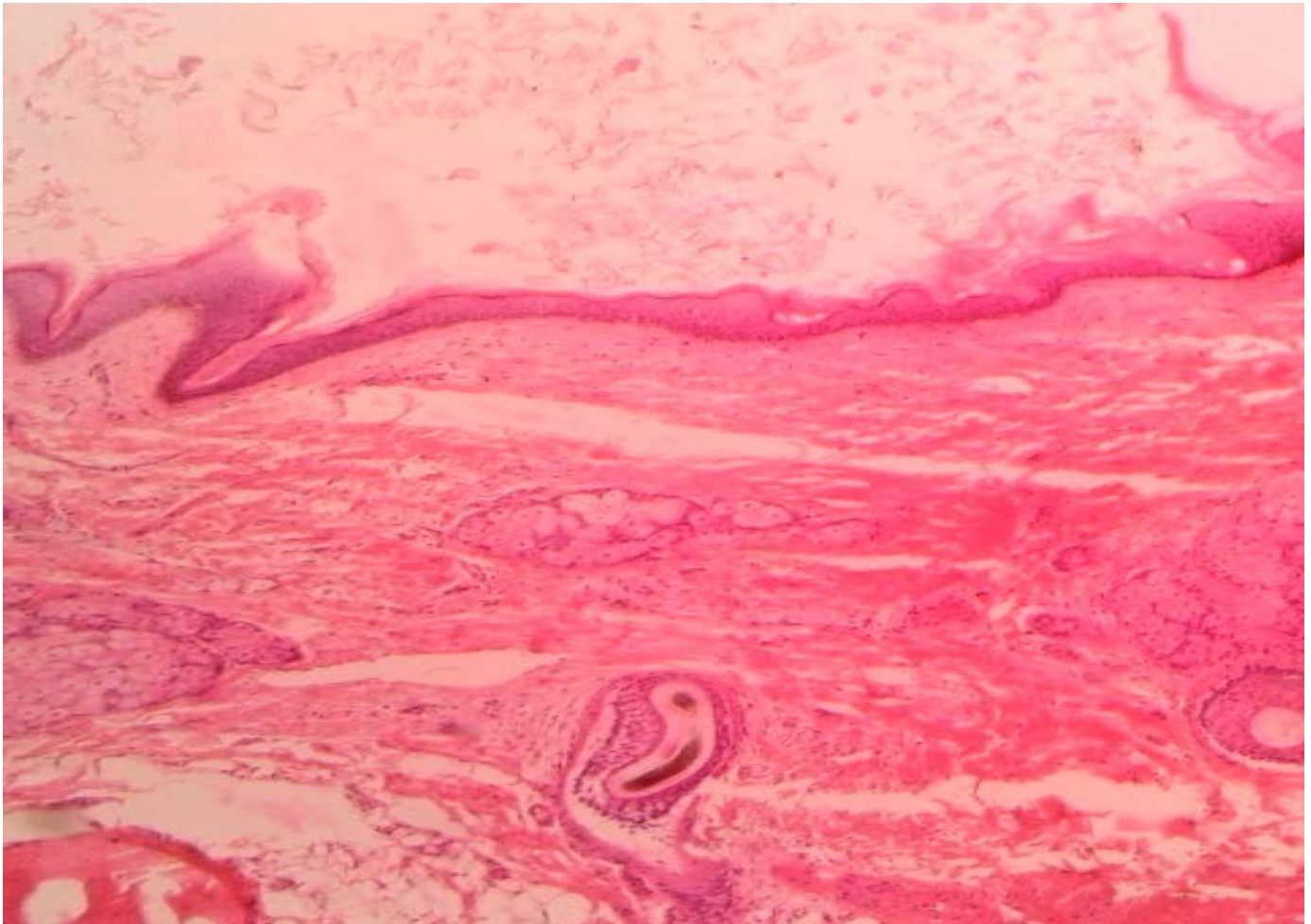
One cyst (1.35%) was filled with friable membranous tissue attached with the wall, and the other cyst (1.54%) had calcified wall. Rokitsky protuberance was noted in 19 (25.67%) cysts; composed of bone, teeth, adipose tissue, soft tissue and thick mucinous content. The tumors which had undergone torsion were dull red brown in color.

### Microscopic features

On histopathological examination, a total of 71 (95.94%) cases of MCTs were purely composed of biphasic or triphasic components of germ layer derivatives.

Germ layer derivatives	Number of patients n(%)
<b>1. Ectodermal derivative</b>	
Skin and adnexa	73(98.64)
<b>Neural tissue</b>	
Glial tissue	8(10.81)
Neurons	3(4.05)
Peripheral nerve	8(10.81)
Melanocytes	3(4.05)
Teeth	2(2.70)
<b>2. Mesodermal derivatives</b>	
Adipose tissue	45(60.81)
Smooth muscle	8(10.81)
Cartilage	16(21.62)
Bone	13(17.56)
Hematopoietic marrow	1(1.35)
Lymphoid tissue	1(1.35)
<b>3. Endodermal derivatives</b>	
Serous and mucinous glands	11 (14.86)
Respiratory epithelium	8(10.81)
Gastrointestinal mucosa	6(8.10)
Thyroid follicles	1(1.35)





**Figure-1: Microscopic features of mature cystic teratoma of the ovary composed of skin and its appendages (H&Estain;10X)**

In three cases, microscopic examination revealed a mixed type of ovarian neoplasms in which the larger component was biphasic or triphasic MCT and the lesser component was of epithelial origin.

In 1 of 3 cases, the lesser component was of mucinous cystadenoma and in other 2 cases, it was serous cystadenoma. The distribution of various mature elements of germ layer derivatives detected in 74 cases of MCT is shown in Table 4. Among all cases, only one was associated with infection and showed accompanying neutrophilic abscess formation.

## Discussion

### Age distribution and MCT

MCTs were encountered mostly at the average age of 30.8 to 35.4 years [4, 12, 17]. In this present study, we found average age of the patient was  $30.87 \pm 12.43$  years. The majority of cases were of patients aged 17-45 years and 20-

30 years [12, 18]. Our findings also corroborates the same, most patients (74.19%) were in reproductive age group of 21-40 years. Early detection of MCT is very important in this context. Conservative ovarian surgery in childhood and adolescence helps in normal puberty also minimize impact on future fertility [19]. In MCT Laparoscopic oophorectomy is the best choice in children and ovarian cystectomy is used in adults [20-22]. The reason, MCT are found in reproductive age group may be because of their development, which is from a single primordial germ cell which has completed meiosis I and meiosis II- is suppressed [23]. Anatomic distribution of teratomas throughout the migration pathway of primordial germ cells from the yolk sac to the gonadal ridges also supports this [24]. Comparing with different other types of germ cell tumors like dysgerminomas, and endodermal sinus tumors, they are most commonly observed. [25-27]; and also the most common tumor among all ovarian neoplasms accounting for 40.3% to 42.8% of all ovarian tumors [27-29]. The incidence of MCTs during pregnancy was 0.2% among ovarian tumors [17] while the incidence was higher in range of 3% to 3.5% in other series



[12, 18] which is comparable with our series. None of these patients had any complications related to the tumors in our study similar to as the case series of Comerci *et al.* [30].

#### **Clinical manifestations associated with MCTs**

MCTs have symptoms related to the size such as pain, urinary and gastrointestinal complaints, and menstrual irregularities [4, 30]. The most common symptom of these tumors was abdominal pain, reported in about half of the cases [12, 29]. In our series, abdominal pain was found in higher incidence about 64.52%, similar to the incidence rate reported by Papadias *et al.* MCTs are often discovered as an incidental finding during a routine physical examination or during pelvic surgery for other reasons [12, 18, 29, 30]. Frequency of asymptomatic patients varied in different series ranging from 16.6 to 75.5% [4, 12, 17, 18, 29, 31]. Of greater interest, an unexpectedly high incidence of asymptomatic patients was reported [17]. In this research, 22.58% of the patients were asymptomatic similar to the study of Ayan *et al.* Torsion of the pedicle was the most common complication of these tumors with the frequency of 3.5 to 9.2% [12, 17, 30, 32]. In contrast, the most common complication in our study was ascites comprising 6.4% and torsion being the second common complication. The most important prognostic factors for malignant transformation are age and tumor diameter [22, 23]. Even though mature cystic teratomas occur frequently during reproductive age group, they do not develop malignancy until after the menopause [31]. Malignant transformation of these tumors is very rare, 0.7 to 1.2% [20, 21], most often in the form of a squamous cell carcinoma [12, 17, 15]. Right-sided mature tumors outnumbered left sided tumors, which is consistent with our study. Bilateral teratomas are uncommon with the reported rate of 8.2 to 16.7% [4, 12, 18, 29, 30, 32]. We observed slightly higher incidence rate (19.35%) of bilateral tumors. Thus, we suggest that in the presence of a unilateral teratoma, careful gross inspection and adequate sections of the contralateral ovary should be kept for histopathological examination. Majority of the tumors (78%) measured 5 to 10 cm in the greatest diameter and only 6 cases were more than 10 cm [18], and approximately 60% measured 5-10 cm in diameter and around 10% were larger than 15 cm [30]. We found, 85% of tumors were 5 to 10 cm, and a relatively less (5.40%) were larger than 10 cm.

#### **Identification of germ layer derivatives**

During the re-evaluation of these tumors classification problems were encountered with the cases of MCTs and epidermoid cysts. The WHO classification of ovarian tumors (2003) separated epidermoid from dermoid cysts [16]. Epidermoid cysts are classified as benign surface epithelial-stromal tumors of the ovary and considered to arise from squamous metaplasia of epithelial elements, and are lined

by stratified squamous epithelium, without evidence of mesodermal or endodermal tissue. There were two cases of epidermoid cysts among all ovarian neoplasms in our institution during the study period of three years. Germ-layer derivatives were ectodermal origin in 98.9%, mesodermal origin in 54.2%, and endodermal origin 29.2% [4]. This is compared to figures of 98.64%, 67.56%, and 36.48% respectively in our series. There were altogether 17 individual derivatives observed in this research work. In our study skin and its appendages were the frequent derivatives, each constituting 98.64%, similar to other studies, whereas it was observed in 100% of the tumors in a case series reported by Ayan *et al.* [4, 27]. The dominant mesodermal structures were bone and/or cartilage either or both were detected in 100% of cases [32]. In contrast, very lower percentage of MCTs had bone and cartilage as such 22.9% bone and 18.7% cartilage reported by Ong HC *et al.*, 19.1% bone and 39% cartilage in series of Sah *et al.*; and 17.56% bone and 21.62% cartilage in our series [4, 27].

#### **Conclusion**

MCT is the most common germ cell tumor that accounts for 49% of all ovarian neoplasm. They occur primarily during the reproductive years, but may occur in postmenopausal women or in children. We found ascites as the most common complication and the prevalence rates of torsion less than those previously reported by most other series. Larger tumors have more risk of undergoing torsion than smaller tumors. The most common germ-layer derivative is ectodermal in origin with high frequency of skin and its appendages. These histopathological findings and the complications will help early diagnosis of MCTs and create awareness among the physicians of Nepal.

#### **Limitations & future scope of the study**

This is a hospital-based study conducted only in a single institution; hence our sample size is less. Thus, it strongly recommended conducting broad spectrum multi-centric studies in future including other districts to explore more information. Apart from this, our study period is relatively less, so prolonged investigations may give more information about MCT.

#### **Abbreviations**

Hematoxylin and Eosin (H&E), Mature cystic teratoma (MCT), World Health Organization (WHO).



## Competing interests

Authors do not have any competing interest.

## Authors' contribution

Dr. Sushna Maharjan designed the study, collected and interpreted the data, drafted the manuscript, and revised it. Dr. Mamata Tiwari and Dr. Sabin Ranabhat also helped in the interpretation of the data, critically revised the manuscript. Final manuscript was approved by all authors.

## Authors' information

**Dr. Sushna Maharjan**, MBBS, MD, Assistant Professor. Department of Pathology, Chitwan Medical College, Bharatpur-10, Chitwan, Nepal.

**Dr. Mamata Tiwari**, MBBS, MD, Associate Professor. Department of Pathology, Chitwan Medical College, Bharatpur-10, Chitwan, Nepal.

**Dr. Sabin Ranabhat**, MBBS, MD, Associate Professor. Department of Pathology, Chitwan Medical College, Bharatpur-10, Chitwan, Nepal.

## Acknowledgments

We would like to thank Mr. Anil Shah and Mr. Santosh Gautam, staffs of histopathology department for their technical assistance in histopathological processing of the specimen.

## References

1. Peterson WF, Prevost EC, Edmunds FT, Hundley JM Jr, Morris FK. Benign cystic teratomas of the ovary; a clinico-statistical study of 1,007 cases with a review of the literature. *Am J Obstet Gynecol* 1955; 70(2):368-82.
2. Matz MH. Benign cystic teratomas of the ovary. A review. *Obstet Gynecol Surv* 1961; 16:591-605.
3. Simon A, Ohel G, Neri A, Schenker JG. Familiar occurrence of mature ovarian teratomas. *Obstet Gynecol* 1985; 66(2):278-9.
4. Ong HC, Chan WF. A clinico-pathological review of benign cystic teratoma of the ovary. *Singapore M J* 1977; 18 (2):100-4.
5. Bughrara FA. Incidence of the histologic types of ovarian tumors in Benghazi (Libya) and Poland. *Neoplasma* 1983; 30(2):251-4.
6. Lakkis WG, Martin MC, Gelfand MM. Benign cystic teratoma of the ovary: a 6-year review. *Can J Surg* 1985; 28(5):444-6.
7. Doss N Jr, Forney JP, Vellios F, Nalick RH. Covert bilaterality of mature ovarian teratomas. *Obstet Gynecol* 1977; 50(6):651-3.
8. Ngwalle KE, Hirawaka T, Tsuneyoshi M, Enjoji M. Osteosarcoma arising in a benign dermoid cyst of the ovary. *Gynecol Oncol* 1990; 37(1):143-7.
9. Aygun B, Kimpo M, Lee T, Valderrama E, Leonidas J, Karayalcin G. An adolescent with ovarian osteosarcoma arising in a cystic teratoma. *J Pediatr Hematol Oncol* 2003; 25(5):410-3.
10. Al-Rayyan ES, Dubqoum WJ, Sawalha MS, Nascimento MC, Pather S, Dalrymple CJ et al. Secondary malignancies in ovarian dermoid cyst. *Saudi Med J* 2009; 30(4):524-8.
11. Caspi B, Appelman Z, Rabinerson D, Zalel Y, Tulandi T, Shoham Z. The growth pattern of ovarian dermoid cysts: a prospective study in premenopausal and postmenopausal women. *Fertil Steril* 1997; 68:501-5.
12. Wu RT, Torng PL, Chang DY, Chen CK, Chen RJ, Lin MC et al. Mature cystic teratoma of the ovary: a clinicopathologic study of 283 cases. *Zhonghua Yi Xue Za Zhi (Taipei)*. 1996;58(4):269-74.
13. Park JY, Kim DY, Kim JH, Kim YM, Kim YT, Nam JH. Malignant transformation of mature cystic teratoma of the ovary: experience at a single institution. *Eur J Obstet Gynecol Reprod Biol*. 2008;141(2):173-8.
14. Lakhey M, Upreti D, Kulshrestha R, Rani S. Massive ovarian edema with contralateral mature cystic teratoma--a case report of an uncommon combination. *Indian J Pathol Microbiol*. 2003;46(2):219-21.
15. Bashyal R, Lee MC. Squamous cell carcinoma arising in ovarian mature cystic teratoma: report of three cases. *Journal of Pathology of Nepal*. 2012;2(3):248-50.
16. Nogales F, Talerman A, Kubik-Huch RA, Tavassoli FA, Devouassoux-Shisheboran M. Germ Cell Tumours. In: Tavassoli FA, Devilee P, eds. *World Health*





- Organisation. Classification of Tumours. Pathology and Genetics Tumours of the Breast and Female Genital Organs. 4th ed. Lyon: IARC press, 2003 pp 163-75.
17. Hursitoglu BS, Demirtas GS, Demirtas O, Akman L, Yilmaz H. A clinico-pathological evaluation of 194 patients with ovarian teratoma: 7-year experience in a single centre. *Ginekol Pol* 2013; 84(2):108-11.
  18. Papadias K, Kairi-Vassilatou E, Kontogiani-Katsaros K, Argeitis J, Kondis- Pafitis A, Greatsas G. Teratomas of the ovary: a clinico-pathological evaluation of 87patients from one Institution during a 10-year period. *Eur J Gynaecol Oncol* 2005; 26(4):446-8.
  19. Azizkhan RG, Caty MG. Teratomas in childhood. *Curr Opin Pediatr*.1996;8(3):287-92.
  20. Mahour GH, Woolley MM, Landing B. Ovarian teratomas in children. *Am J Surg.*, 1976;132(5): 587-9.
  21. Bollen N, Camus M, Tournaye H. Munck LD, Devroey P. Laparoscopic removal of benign mature cystic teratoma. *Hum. Reprod.* 1992;7(10):1429-32.
  22. Canis M, Bassil S, Wattiez A, Pouly JL, Manhes H, Mage G *et al.* Fertility following laparoscopic management of benign adnexal cysts. *Hum. Reprod.* 1992; 7(4):529-31.
  23. Linder D, McCaw BK, Hecht F. Parthenogenic origin of benign ovarian teratomas. *N Engl J Med.* 1975;292(2):63-6.
  24. Talerman A. Germ cell tumors of the ovary. In: RJ Kurman. *Blaustein's Pathology of the Female Genital Tract.* 5th. New York: Springer; 2002:994.
  25. Bhattacharya MM, Shindhe SD, Purandare VN. A clinicopathological analysis of 270 ovarian tumours. *J Postgrad Med* 1980; 26(2):103-7.
  26. Khan AA, Luqman M, Jamal S, Mamoon N, Mushtaq S. Clinicopathological analysis of ovarian tumours. *Pak J Pathol* 2005; 16(1):28-32.
  27. Sah SP, Uprety D, Rani S. Germ cell tumors of the ovary: A clinicopathologic study of 121 cases from Nepal. *J Obstet Gynaecol Res* 2004; 30 (4):303-8.
  28. Jha R, Karki S. Histological pattern of ovarian tumors and their age distribution. *Nepal Med Coll J* 2008; 10 (2):81-5.
  29. Ayhan A, Bukulmez O, Genc C, Karamursel BS, Ayhan A. Mature cystic teratomas of the ovary: case series from one institution over 34 years. *Eur J Obstet Gynecol Reprod Biol* 2000; 88(2):153-7.
  30. Comerchi JT Jr, Licciardi F, Bergh PA, Grerori C, Breen JL. Mature cystic teratoma: a clinicopathologic evaluation of 517cases and review of the literature. *Obstet Gynecol* 1994; 84 (1):22-8.
  31. Pantoja E, Rodriguez-Ibanez I , Axtmayer RW, Noy MA, Pelegrina I. Complications of dermoid tumors of the ovary. *Obstet Gynecol* 1975; 45 (1):89-94.
  32. Ayhan A, Aksu T, Develioglu O, Tuncer ZS, Ayhan A. Complications and bilaterality of mature ovarian teratomas (clinicopathological evaluation of 286 cases). *Aust N Z J Obstet Gynaecol* 1991; 31(1):83-5.