

Pemphigus Foliaceus with herpes simplex virus; a case report



Bansal N¹, Mohan S²

Correspondence to:

drnalibansal@yahoo.com

¹**Dr. Nalini Bansal**, MD, DNB, PDCC, MNAMS, Senior Histopathologist, Department of Histopathology, Fortis Hospital, Fortis Faridabad, Haryana, India.

²**Dr. Swati Mohan**, MD, Senior Consultant dermatology, Fortis Hospital, Fortis Faridabad, Haryana, India.

Editors for this Article:

Dr. A.K. Pradhan, MD, Professor, KIMS, Amalapuram, Editor-in-Chief, Medical Science.

Dr. Arnab Ghosh, MD, Professor, Pathology, MCOMS, Pokhara, Nepal, Editorial board member, Medical Science.

Cite this article:

Bansal N, Mohan S. Pemphigus Foliaceus with herpes simplex virus; a case report. Medical Science. 2016; 4(4):343-8.

Information about the article

Received: May. 18, 2016

Revised: Mar 25, 2017

Accepted: Mar 28, 2017

Published online: Mar 30, 2017

DOI: <http://dx.doi.org/10.29387/ms.2017.4.4.343-348>

Abstract

Pemphigus foliaceus is an autoimmune disease having a chronic generalized course or may rarely present as an exfoliative dermatitis. Presence of occult HSV infection is involved in development of pemphigus and immunosuppressive therapy for pemphigus results in flare of typical or atypical herpetic lesions. We herein report of a case of a 48 year old male on immunosuppressive therapy for pemphigus foliaceus resulting in flare of herpetic infection.

Key words

Etiology, Follicular, Herpes, immunosuppression, Pemphigus



Background

Pemphigus are group of blistering disorders of autoimmune etiology affecting skin and/ or mucous membrane. Pathogenesis of these group of diseases includes formation of antibodies against adhesion molecules on keratinocytes. [1]. Most cases are localized to the face and trunk characterized by recurrent formation of flaccid bullae which can rupture, resulting in formation of shallow erosions and erythematous plaques. Rarely it can also present as generalized erythroderma [2], Management requires immunosuppressive therapy.

Rarely herpes simplex virus infection can develop as a consequence of immunosuppressive therapy in these patients and causes a clinical diagnostic dilemma. Definite diagnosis is essential as management than requires immunosuppressive therapy with antiviral drugs.

Case Report

We report a case of a 48-year-old male who presented with complaints of itching off and on, scaly plaque on face and entire body since 3 years [Figure 1], visited Fortis Hospital, Faridabad, Haryana, India.

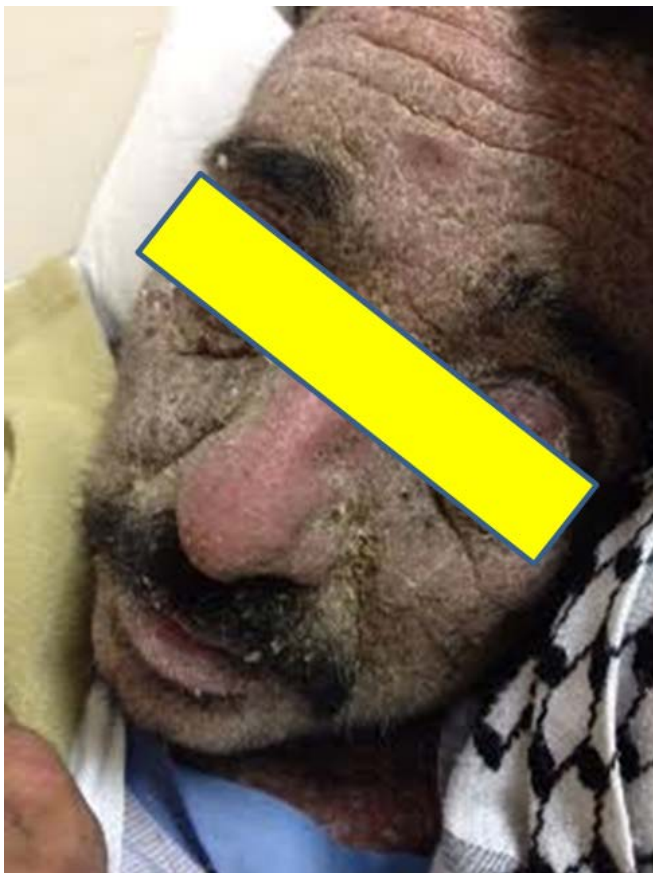

Figure 1-Erythrodermic stage of pemphigus foliaceus

He has taken treatment with partial relief. There were no complaints of photosensitivity, malar rash, discoid rash, photosensitivity and other systemic complaints. There were no complaints of any blister, eye involvement, and oral mucosa involvement. Patient was in erythrodermic phase. He also had history of left orchidectomy with a healthy wound there. He has also history of uncontrolled blood sugar.

On General examination his blood pressure was 90/60 mmHg, pulse 88/min, Respiratory rate 24/min and temperature was 98.4 °F. His chest, cardiovascular, central nervous system and per abdomen examination were unremarkable. Investigation done showed Hemoglobin of 11.0 mg/dl, TLC 17,200 /cumm, DLC (N83,E00,L08,M09), ESR was high 25 mm/ hour, APTT was high 16.9 sec, INR -1.47, LFT showed bilirubin 0.43 mg/dl, total protein 4.3g/dl, low SGOT -13IU/L, SGPT-23 IU/L, Low serum sodium-121mEq/l, low serum creatinine-0.7mg/dl. Fungal smears were negative. X ray chest was normal. CRP was high 186.19 mg/l. Urine examination showed protein traces WBC -20-30/HPF, bacteria detected (+). Aerobic culture was positive for staphylococcus aureus. USG whole abdomen showed mild hepatomegaly. USG KUB Scan was normal. Antinuclear antibody was positive, primary dilution 1:40. His skin biopsy was taken. Biopsy showed mild irregular epidermal acanthosis with focally stripped off corneal layer, blister base showing scattered dyskeratotic granular keratinocytes. Dermis show mildly increased perivascular lymphocytic infiltrate. Features suggestive of pemphigus foliaceus [Figure-2]. Direct immunofluorescence done show lace like positivity for IgG at intercellular junction in full thickness of epidermis consistent with pemphigus foliaceus.

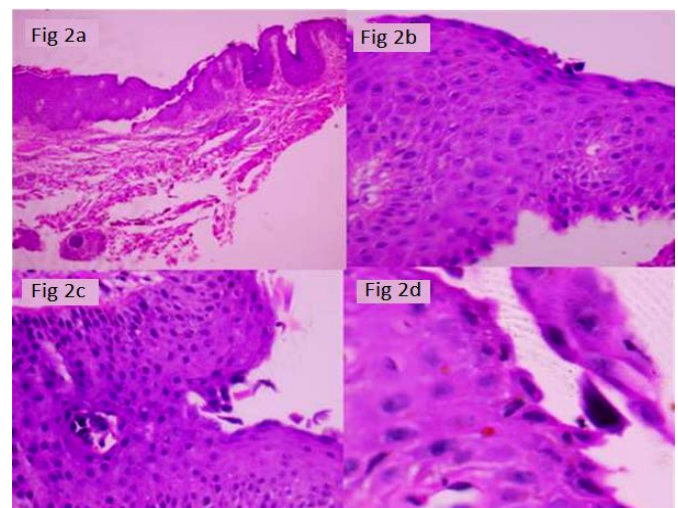


Figure – 2 First Biopsy

Fig 2a-Mild epidermal acanthosis with focally stripped of corneal layer (H&EX4), Fig 2b-Stripped off area show



occasional dyskeratotic keratinocytes (H&EX20), Fig 2c-Foci showing dyskeratotic keratinocytes (H&EX40), Fig 2d-Dyskeratotic keratinocytes (H&EX100)

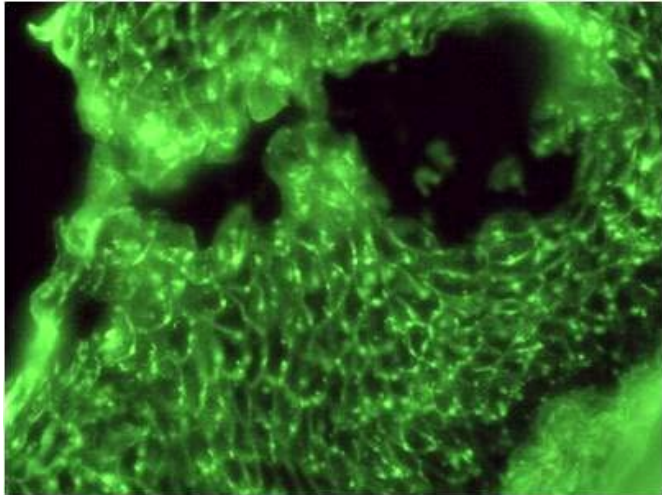


Figure - 3 DIF showing lace like positivity for IgG

Patient was treated with high dose of steroid along with azathioprine (Omnacortil [Prednisolone] 20 mg 1 tab once a day, Azoran 50mg 1 tab twice a day) over a period of 25 days. Following treatment patient's lesions partially subsided however fresh lesions appeared around the lips, eyes and chest and a rebiopsy was taken from chest wall lesion.

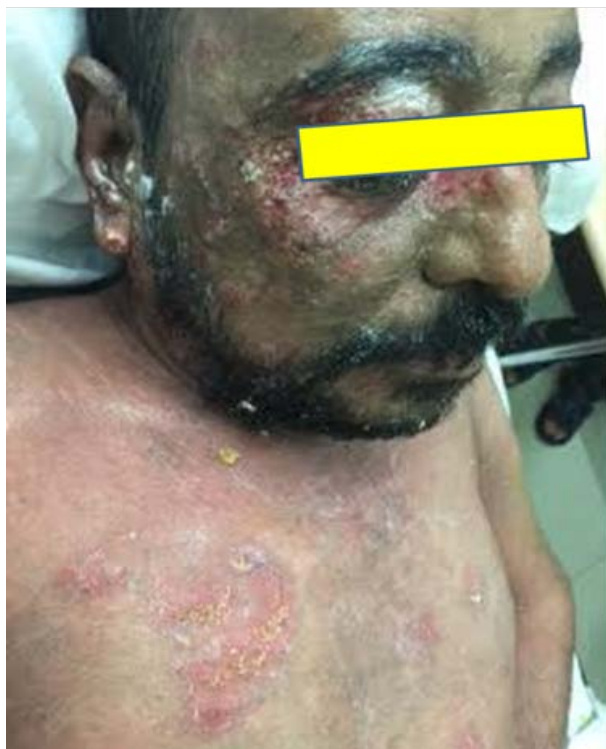

Figure 4 - Fresh lesions around eyes, oral cavity and chest wall

Section from the biopsy shows acantholysis in upper dermis within and adjacent to granular layer. Focally detached stratum corneum with several dyskeratotic granular keratinocytes and eosinophilic spongiosis also noted. Another focus in the biopsy show ballooning degeneration of the cells with homogenous eosinophilic inclusion and ground glass nuclei noted. Occasional multinucleate cells also seen.

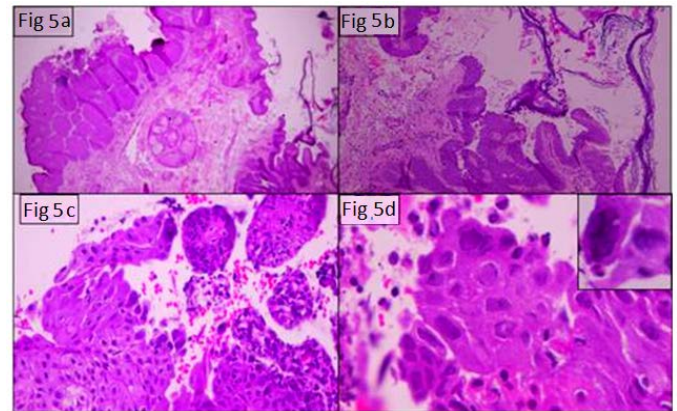


Figure-5: 2nd Biopsy

Fig. 5a-Moderate epidermal acanthosis with sub corneal acantholytic blister (H&EX4), Fig. 5b-Subcorneal acantholytic blister (H&EX20), Fig. 5c-Another foci showing ulcerated surface with enlarged nuclei showing ground glass appearance (H&EX20), Fig. 5d-Ground glass nuclei with multinucleate cells (inset) [H&EX100]

Histopathology features were suggestive of pemphigus foliaceus with herpetic inclusion.

Serological testing done for HSV Type 1, IgG was positive (6.05) and HSV type 2 IgG was positive (3.31) [<0.8 negative, $0.8-1.2$ indeterminate and >1.2 positive]. Patient was started on antiviral therapy along with immunosuppressive therapy.

Discussion

Pemphigus foliaceus is an autoimmune disease having a chronic generalized course or may rarely present as an exfoliative dermatitis. Clinically patient presents with flaccid bullae that usually arise on an erythematous base or as scaling patches without evident blisters [3]. Erythema, oozing, and crusting can be present. Because of their superficial location, the blisters break easily, leaving shallow erosions. Mucosal involvement is absent even with widespread disease. The Nikolsky sign is positive, and Tzanck smear preparation reveals acantholytic granular keratinocytes [4].



It is an autoimmune disease characterized by formation of antibodies against desmoglein 1 present mostly in upper layers of the epidermis.

Histologically characterized by superficial epidermal /sub corneal acantholytic blister. Presence of dyskeratotic granular keratinocytes is very characteristic. As also seen in the first biopsy of our patient where no definite blister was seen but only presence of dyskeratotic keratinocytes were clues for the diagnosis.

Direct immunofluorescence in patients of pemphigus foliaceus show intercellular deposition of IgG either in superficial portion or full thickness of epidermis. Similar lace like deposition of IgG was noted within full thickness of epidermis in our case consistent with diagnosis of pemphigus.

Patient was treated with immunosuppressive therapy which resulted in flare of disseminated herpes.

Role of HSV infection in etiopathogenesis of pemphigus has long been debated. The associations of herpes with pemphigus have been studied by several groups [5-13]. [Table1].

Role of HSV in etiopathogenesis of pemphigus was first described by Krain in 1974 in an study on 59 patients where they found that after herpetic infection two patients developed pemphigus [5].

Schlupen *et al* reported 3 patients suffering from pemphigus vulgaris had exacerbation of oral mucosal lesion due to secondary herpes virus infection [6]. Tufano *et al*. have investigated the presence of various infections including herpes virus 1/2, EBV, CMV, and HHV-6 in 20 patients with pemphigus using serology and PCR in peripheral blood mononuclear cells (PBMC) and also in biopsy samples. Majority of these patients (19/20) had positive serology for CMV and HSV [7]. Belgnaoui *et al* in a study on 141 patients found that herpes infection was seen in only 19% patients [8]. Nikkels *et al* studied presence of HSV in acantholytic disorders, including 19 patients of pemphigus vulgaris for possible occult viral colonization. No cytopathic signs suggestive of HSV were seen. However, IHC revealed HSV antigens in pemphigus vulgaris (1/19, HSV-I). They concluded that occult HSV colonization may occur in pemphigus vulgaris. Because of the frequent use of immunosuppressive treatments for primary bullous disorders, a careful watch on HSV colonization should be kept [9].

Caldarola *et al* reported 3 cases of pemphigus vulgaris with secondary HSV1 infection patients on immunosuppressive treatment [10]. Marzano *et al* in 2009 in a study on 35 patients tried to evaluate the association of herpes with pemphigus with the hypothesis of whether HSV infection represents an aetiopathogenetic factor for pemphigus or a consequence of the immunosuppressive treatment. They analyzed Skin and/or mucosal swabs from 35 patients infected with pemphigus vulgaris or pemphigus foliaceus for HSV by polymerase chain reaction. They concluded that HSV in pemphigus lesions arises as a frequent and early complication of immunosuppression [1]. Another study by Esmaili *et al* detected the presence of HSV 1 and 2 (herpes simplex virus) and HHV8 (human herpesvirus 8) in patients suffering from pemphigus vulgaris by using PCR in an study on 38 patients. They could not detect these viruses in any of these patients [11].

Another retrospective study by Esmaili *et al* in 2013 on 155 patients of pemphigus 9.68% were found to have localized herpes simplex infection [12]. In a recent study in 2013 by Mahnaz Banihashmi *et al* 30 diagnosed cases of pemphigus were analysed for presence of HSV1, EBV, HSV2 and HHV8 by immunohistochemistry. They found significant prevalence of HSV1 in lesions of pemphigus patients, especially in pemphigus foliaceus [13]. There have been several case reports of pemphigus with associated herpes virus infection mostly seen as a complication of immunosuppressive therapy as in our case [14-21] [Table 2].

No	Author s	Journal	Year	No of patient s	Conclusion
1	Krain LS	Arch Dermatol	1974	59	HSV
2	Schlupen EM <i>et al</i>	Dermatology	1996	3	Secondary HSV to immunosuppression
3	Tufno MA <i>et al</i>	Br J dermatol	1999	20	Viral infection may only be an occasional factor triggering the outbreak or exacerbation of disease
4	Belgnaoui FZ <i>et al</i>	Presse Medicale	2007	141	19%% patients developed herpes infection
5	Nikkels AF <i>et al</i>	Am J Clin Dermatol	2008	19	Occult HSV colonization may occur in pemphigus vulgaris
6	Caldarola G <i>et al</i>	Eur J Dermatol	2008	3	Complication of immunosuppression

Few believe that presence of herpes acts as an etiological, triggering agent for pemphigus whereas others believe that it is a result of immunosuppressive drugs used for pemphigus.



Table 2 – Case reports of Pemphigus associated with Herpes

No	Author	Journal	Year	Age of patient	Location of lesion
1	Grunwald MH <i>et al</i> [14]	International Journal of Dermatology 1986;25(6):392-3.	1986	39 year male	Oral lesion
2	Brown P <i>et al</i> [15]	Journal of the American Academy of Dermatology, 21(5):1126-8	1989	55 year male	Oral lesion
3	Prendiville JS <i>et al</i> [16]	PediatrDermatol. 1994;11:145-50.	1994	11 year girl	Oral lesion
4	Takahashi I <i>et al</i> [17]	Diagn Cytopathol. 1998;19:446-50	1998	53 year female	Oral lesion
5	Hale EK <i>et al</i> [18]	J Eur Acad Dermatol Venereol.1999;13:221-3.	1999	69 year old female	Oral Lesion
6	Kalajian AH [19]	Australas J Dermatol. 2007; 48:242-7.	2007	57 year female	Erosive Genital lesion
7	Brandão ML <i>et al</i> [20]	Rev Inst Med Trop Sao Paulo. 2011;53(2):113-7.	2011	50 year female	Eyelid
8	Cheng HF <i>et al</i> [21]	Hong Kong J. Dermatol. Venereol. 2013;21;73-7	2013	80 year male	face, upper trunk and proximal extremities, Chest wall
9		Present Case	2014	48 year old male	Oral lesions, lesion around eye and chest wall

Conclusion

With the above studies it could be concluded that occult HSV infection may be one of the occasional factors involved in development of pemphigus and immunosuppressive therapy for pemphigus results in flare of typical or atypical herpetic lesions. However more randomized studies on a larger number of patients are required on screening for occult herpes in erythrodermic pemphigus patients for substantiating the findings. For the practicing dermatologist, herpetic infection should be considered in pemphigus patients who lack improvement with adequate immunosuppressive therapy or development of fresh lesions after partial response.

Competing interests

Authors do not have any competing interest.

Authors' contribution

NB reported, and studied the case thoroughly; drafted the manuscript, and revised it. SM revised the manuscript. Final manuscript was approved by all authors.

Acknowledgments

We would like to thank the patient for his support. We would also like to thank the technical team including Mr. Naman, Mrs. Pooja and Mr. Ramesh Joshi for their support.

Reference

1. Marzano AV, Tournalaki A, Merlo V, Spinelli D, Venegoni L, Crosti C. Herpes simplex virus infection and pemphigus. *Int J Immunopathol Pharmacol.* 2009;22(3):781-6
2. Generalized erythrodermic pemphigus foliaceus in a child and its successful response to rituximab treatment. *Pediatr Dermatol.* 2007; 24(2):172-6.
3. Freedberg, et al. *Fitzpatrick's Dermatology in General Medicine.* 6th ed. McGraw-Hill, 2003. pp 558-62.
4. Hong Wu, Schapiro B, Harrant TJ. Noninfectious Vesiculobullous and Vesiculopustular Diseases. *Lever's Histopathology of the Skin,* 9th ed, 2005;258
5. Krain LS. Pemphigus: epidemiologic and survival characteristics of 59 patients, 1955-1973. *Arch Dermatol.* 1974;110:862-5
6. Schlupen EM, Wollenberg A, Hänel S, Stumpfenhausen G, Volkenandt M. Detection of herpes simplex virus in exacerbated pemphigus vulgaris by polymerase chain reaction. *Dermatology.* 1996; 192:312-6.
7. Tufano MA, Baroni A, Buommino E, Ruocco E, Lombardi M, Ruocco V. Detection of herpesvirus DNA in peripheral blood mononuclear cells and skin lesions of patients with pemphigus by polymerase chain reaction. *Br J Dermatol* 1999; 141:1033-9
8. Belgnaoui FZ, Senouci K, Chraïbi H, Aoussar A, Mansouri F, Benzekri L *et al.* Predisposition to infection in patients with pemphigus. *Retrospective*



- study of 141 cases, *Presse Medicale* 2007; 36(11):1563-9.
9. Nikkels AF, Delvenne P, Herfs M, Pierard GE. Occult herpes simplex virus colonization of bullous dermatitides. *Am J Clin Dermatol* 2008;9:163-8
 10. Caldarola G, Kneisel A, Hertl M, Feliciani C. Herpes simplex virus infection in pemphigus vulgaris: clinical and immunological considerations. *Eur J Dermatol* 2008;18:440-3.
 11. Esmaili N, Hallaji Z, Abedini R, Soori T, Mortazavi H, Chams-Davatchi C. Pemphigus vulgaris and herpesviruses: is there any relationship? *International Journal of Dermatology* 2010; 49(11);1261-5.
 12. Esmaili N, Mortazavi H, Noormohammadpour P, Boreiri M, SooriM, Farahani IM,5 and MitraMohit M. Pemphigus Vulgaris and Infections: A Retrospective Study on 155 Patients. *Autoimmune Diseases*. 2013, Article ID 834295.
 13. Banihashemi M, Maleki M, Pezeshkpoor F, Jafarian AH, Sharghi MR, Hashemzadeh S. Incidence of herpes family viruses in skin lesions of pemphigus patients. *Iran J Dermatol* 2013; 16(64):53-6.
 14. Grunwald MH, Katz I, Friedman-Birnbaum R. Association of pemphigus vulgaris and herpes simplex infection. *Int J Dermatol*. 1986;25:392-3.
 15. Brown P, Taylor B. Herpes simplex infection associated with pemphigus vulgaris. *Journal of the American Academy of Dermatology*, 1989; 21(5) :1126 -8
 16. Prendiville JS, Israel DM, Wood WS, Dimmick JE. Oral pemphigus vulgaris associated with inflammatory bowel disease and herpetic gingivostomatitis in a 11-year-old girl. *PediatrDermatol*. 1994;11:145-50.
 17. Takahashi I, Kobayashi TK, Suzuki H, Nakamura S, Tezuka F. Coexistence of pemphigus vulgaris and herpes simplex virus infection in oral mucosa diagnosed by cytology, immunohistochemistry, and polymerase chain reaction. *Diagn Cytopathol*. 1998;19(6):446-50.
 18. Hale EK, Bystryn JC. Atypical herpes simplex can mimic a flare of disease activity in patients with pemphigus vulgaris. *J Eur Acad Dermatol Venereol*. 1999; 13:221-3.
 19. Kalajian AH, Callen JP. Atypical herpes simplex infection masquerading as recalcitrant pemphigus vulgaris. *Australas J Dermatol*. 2007;48:242-7.
 20. Brandao, Maria Luiza Figueiredo Braga *et al.* Refractory pemphigus vulgaris associated with herpes infection: case report and review. *Rev. Inst. Med. trop. S. Paulo* 2011;53(2):113-17.
 21. Cheng HF, Lam MS, KH Tsang KH, Ho WC, Ng WF, Kwan WK. Pemphigus foliaceus complicated by disseminated cutaneous herpes simplex virus infection in an elderly man. *Hong Kong J. Dermatol. Venereol*. 2013;21;73-7.